

CASE REPORT

Depression of the elderly revealing a primary hypothyroidism

Salem Bouomrani^{1,2*} Mouna Guerhazi^{1,2} Souad Yahyaoui¹ Safa Trabelsi¹ Latifa Ghanmi^{2,3}

Abstract: **Introduction** Psychiatric manifestations are exceptional during hypothyroidism and are not always easy to diagnose, especially since the clinical signs of hypothyroidism can be confused with those of the depressive syndrome. We report an original observation of depression of the elderly revealing an isolated primary hypothyroidism. **Observation** A 78-year-old patient, followed for essential hypertension, well-balanced under monotherapy with calcium channel blockers, and without degenerative complications, was referred by her family doctor for depressive syndrome not improved by the specific treatment prescribed and correctly taken for six months. The clinical examination noted in particular macroglossia with dental impressions and dry and cracked skin. The biological assessment showed hypothyroidism with TSH at $28\mu\text{mol/l}$. Thyroid ultrasound showed atrophy of the thyroid gland. The thyroid autoimmunity (anti-thyroglobulin and anti-thyroperoxidase antibodies) was negative. The rest of the biological tests were in the normal range. The diagnosis of Riedel's thyroiditis was retained and the patient was treated with levothyroxine in progressive doses until TSH normalization was achieved. The evolution on the psychiatric level was also favorable with disappearance of the signs of the depression and the anti-depressive treatment was discontinued. **Conclusion** Depression is rare, complicating only 4% of overt hypothyroidism and its diagnosis is not always easy, especially in the elderly. Hormone replacement therapy significantly improves the depressive syndrome and protects against cognitive decline. Thus, hypothyroidism screening seems appropriate for any depressive syndrome in the elderly.

Keywords: depression, hypothyroidism, elderly

1 Introduction

Hypothyroidism is a very common endocrinopathy. The prevalence of overt/symptomatic forms of hypothyroidism varies from 0.2 to 5.3% depending on the series according to the definitions and retained threshold values of the thyroid hormones.^[1] Subclinical/asymptomatic forms of hypothyroidism are by far the most common with prevalence exceeding 10% in most studies and populations.^[2] Subclinical hypothyroidism is particularly common in elderly with prevalence of up to 20% in subjects over 60 years,^[3,4] and we estimate that 2.5% of subjects with subclinical hypothyroidism progress annually towards an overt form.^[5]

Despite their frequency and ease of diagnosis, these endocrinopathies remain underdiagnosed; a meta-

analysis of studies in nine European countries estimated the prevalence of undiagnosed cases of hypothyroidism (both overt and subclinical) at 5% of the general population.^[6]

This difficulty is mainly due to the large clinical polymorphism of this disease with sometimes so-called "unusual" modes of revelation:^[1] rheumatologic,^[7] digestive,^[8] neuromuscular,^[9] cardiac,^[2] and psychiatric^[10] justifying the qualification of "great simulator" attributed to this endocrinopathy.^[11]

We report an original observation of primary hypothyroid in the elderly revealed by an isolated depressive syndrome.

2 Case report

A 78-year-old patient, followed for essential hypertension, well-balanced with calcium channel blockers and without degenerative complications, was referred by her family doctor for depressive syndrome not improved by the specific treatment prescribed and correctly taken for six months.

His symptomatology was insomnia, sadness of mood, asthenia, and loss of vital impetus.

The basic biological tests (blood count, creatinine, serum calcium, erythrocyte sedimentation rate, fasting

Received: January 11, 2019; Accepted: Tuesday 1, 2019; Published: Tuesday 3, 2019

* Correspondence to: Salem Bouomrani, Department of Internal medicine, Military Hospital of Gabes, Gabes 6000, Tunisia; Sfax Faculty of Medicine, University of Sfax, Sfax 3029, Tunisia Email: salembouomrani@yahoo.fr

¹ Department of Internal medicine, Military Hospital of Gabes, Gabes 6000, Tunisia.

² Sfax Faculty of Medicine, University of Sfax, Sfax 3029, Tunisia.

³ Department of Psychiatry, Gabes Regional Hospital, Gabes 6000, Tunisia.

Citation: Bouomrani S, Guerhazi M, Yahyaoui S, *et al.* Depression of the elderly revealing a primary hypothyroidism. *Adv Gen Pract Med*, 2019, 2(1): 1–4.

Copyright: © 2019 Salem Bouomrani, *et al.* This is an open access article distributed under the terms of the [Creative Commons Attribution License](https://creativecommons.org/licenses/by/4.0/), which permits unrestricted use, distribution, and reproduction in any medium, provided the original author and source are credited.

blood glucose, transaminases, total cholesterol, triglycerides, and ionogram) as well as the cerebral computed tomography requested by his family doctor were without abnormalities.

No particular family or personal psychiatric history was revealed. Similarly, no recent traumatic event or specific drug or toxic intake was reported.

The clinical examination in our department noted in particular a macroglossia (Figure 1) with bilateral dental impressions (Figure 2) and dry and cracked skin (Figure 3). The biological assessment showed hypothyroidism with Thyroid Stimulating Hormone (TSH) at $28 \mu\text{mol/l}$ and a total thyroxine at 2 pmol/l . Thyroid ultrasound showed atrophy of the thyroid gland. The thyroid autoimmunity (anti-thyroglobulin and anti-thyroperoxidase antibodies) was negative. The rest of the biological tests were in the normal range. The diagnosis of overt primary hypothyroidism by Riedel's thyroiditis was retained and the patient was put on levothyroxine in progressive doses until normalization of TSH.

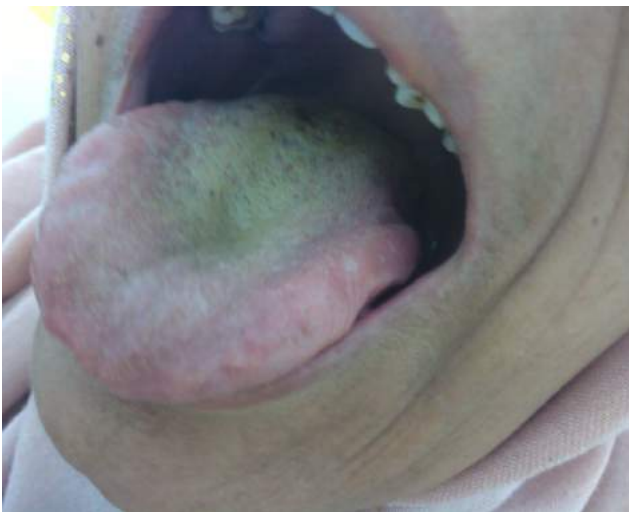


Figure 1. Macroglossia

The evolution on the psychiatric level was also favorable with disappearance of the signs of the depression and anti-depressive treatment was discontinued. No recurrence of depressive symptoms has been noted for six years.

3 Discussion

Hypothyroidism is a common condition in the elderly and often under-diagnosed especially in its asymptomatic forms (subclinical hypothyroidism).^[12] The diagnosis of depression associated with hypothyroidism is even more difficult, even in the overt forms of this endocrinopathy because these two conditions share several

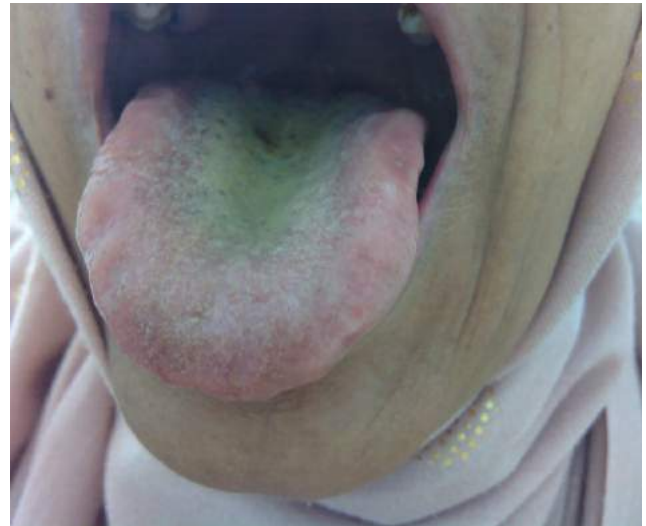

Figure 2. Macroglossia with bilateral dental impressions

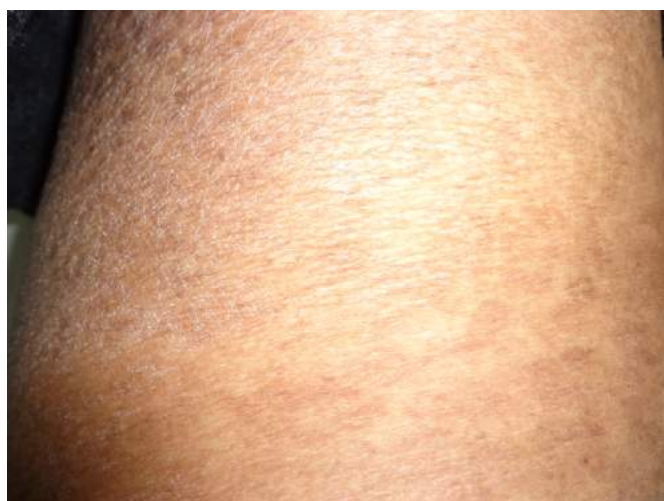clinical features,^[13,14] and often the clinical signs of hypothyroidism can lend confusion with those of the depressive syndrome.^[15]

The psychiatric manifestations are seen in 5 to 15% of the primary hypothyroidism^[16] and are also frequent during subclinical hypothyroidism,^[17] and particularly in the elderly.^[13,17] Psychiatric manifestations associated with hypothyroidism include cognitive impairment, affective disorders, dementia, encephalitis, and psychosis.^[2] These manifestations may be severe,^[18,19] and may exceptionally reveal the disease.^[10,18]

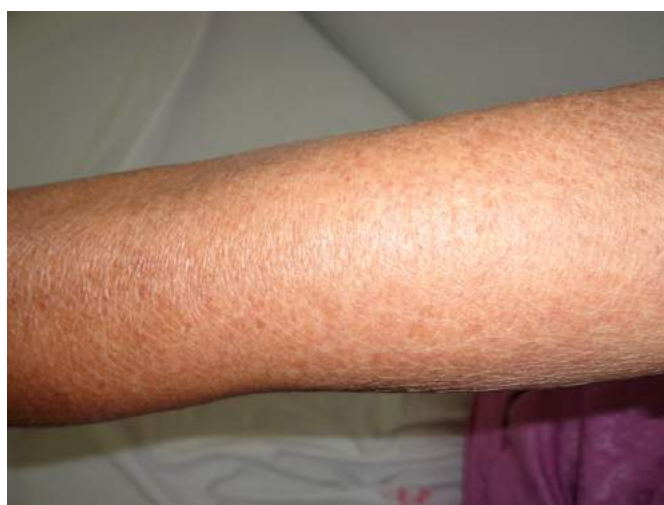Depression remains rare, complicating only 4% of overt hypothyroidism^[20] and is often characterized by its severity and its resistance to antidepressant therapy.^[21,22] Indeed, the multicenter European study of resistant depression (GSRD Study) performed on 1410 patients, showed that 13% of subjects with a major depressive syndrome had underlying hypothyroidism.^[21]

This depression appears to be more common in elderly subjects, particularly women, and it has been shown that hypothyroid women are significantly predisposed to the development of depressive syndrome regardless of their basic demographic and socio-economic characteristics.^[20]

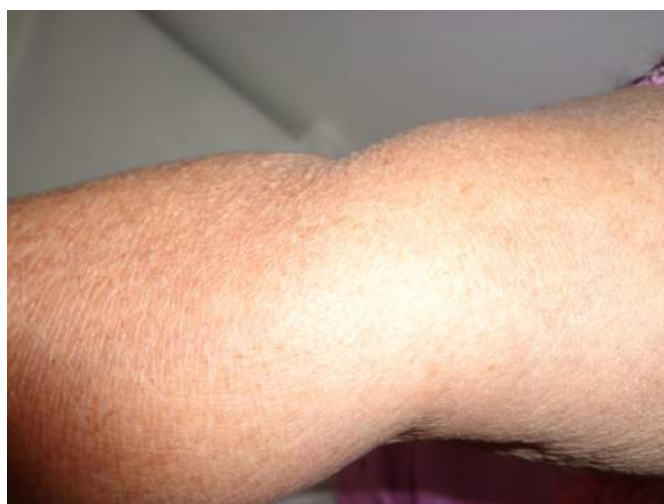The particular frequency of depression during hypothyroidism suggests common mechanisms to the point that several authors present the hypothesis of "brain hypothyroidism" to explain the pathogenesis of depression during this endocrinopathy.^[13] This theory is based on the effects of deprivation in thyroid hormones on brain tissue, and on the direct effects of thyroid pathology, especially autoimmune thyroiditis.^[17] Indeed, Siegmann EM meta-analysis in 2018 demonstrated a significant association between hypothyroidism by autoimmune thy-



(a)



(b)



(c)

Figure 3. (a) Dry and desquamative skin at the level of the abdominal wall; (b) Dry and flaking skin giving the appearance of "snake skin" at the level of the right forearm; (c) Dry and scaly skin on the right shoulder and arm.

roiditis and depression with an odds ratio of 3.56.^[22] The high levels of pro-inflammatory cytokines during these thyroiditis, particularly interleukin-6 (IL-6), and tumor necrosis factor-alpha (TNF- α), are involved in the pathogenesis of associated depressive syndromes.^[23]

In overt forms, the simple hormone replacement therapy of hypothyroidism significantly improves and even eliminates mood disorders, including depression, in these subjects.^[15, 17-20] In the subclinical forms of hypothyroidism, and even in the absence of consensus, the presence of neuropsychiatric manifestations is an indication for hormone replacement therapy.^[24]

In this context, the interesting study of Talaei A et al allowed to define a "TSH cut off point" associated with depression in patients treated for hypothyroidism. It seems that depression is significantly associated with a cut off of 2.5 $\mu\text{mol/l}$ and severe depression with a TSH cut off point of 4 $\mu\text{mol/l}$.^[13] Thus the optimal TSH recommend in hypothyroid treated subjects to avoid the development of depressive syndrome is 2.5 $\mu\text{mol/l}$.^[13]

4 Conclusion

Hypothyroidism revealed by psychiatric manifestations is not always easy to diagnose in the elderly. This depression does not seem to depend on the value of TSH and can be seen in both overt and subclinical hypothyroidism. Thus, it is advisable to ask a TSH for any depressive syndrome in the elderly to diagnose an underlying hypothyroidism early, and improve the prognosis by improving the quality of life and avoiding cognitive decline.

5 Conflicts of interest

The authors declared that they have no conflicts of interest to this work.

References

- [1] Chaker L, Bianco AC, Jonklaas J, et al. Hypothyroidism. *Lancet*, 2017, **390**(10101): 1550-1562. [https://doi.org/10.1016/S0140-6736\(17\)30703-1](https://doi.org/10.1016/S0140-6736(17)30703-1)
- [2] Udovicic M, Pena RH, Patham B, et al. Hypothyroidism and the Heart. *Methodist Debakey Cardiovasc J*, 2017, **13**(2): 55-59. <https://doi.org/10.14797/mdcj-13-2-55>
- [3] Baumgartner C, Blum MR, Rodondi N. Subclinical hypothyroidism: summary of evidence in 2014. *Swiss Med Wkly*, 2014, **144**: w14058. <https://doi.org/10.4414/smw.2014.14058>
- [4] Decandia F. Risk factors for cardiovascular disease in subclinical hypothyroidism. *Ir J Med Sci*, 2017, May 10. doi: 10.1007/s11845-017-1617-9. [Epub ahead of print] <https://doi.org/10.1007/s11845-017-1617-9>

- [5] Redford C, Vaidya B. Subclinical hypothyroidism: Should we treat? *Post Reprod Health*, 2017, **23**(2): 55-62.
<https://doi.org/10.1177/2053369117705058>
- [6] Garmendia Madariaga A, Santos Palacios S, Guilln-Grima F, *et al.* The incidence and prevalence of thyroid dysfunction in Europe: a meta-analysis. *J Clin Endocrinol Metab*, 2014, **99**(3): 923-31.
<https://doi.org/10.1210/jc.2013-2409>
- [7] Bouomrani S, Regaeg N, Ben Hamad M, *et al.* An Unexpected Etiology of Rhizomelic Pseudo-Polyarthrits (Polymyalgia Rheumatica) in the Elderly. *Archives of Orthopedics and Rheumatology*, 2018, **1**(1): 12-16.
- [8] Bouomrani S, Lassoued N, Ben Hamad M, *et al.* Recurrent Intestinal Obstruction Revealing Hypothyroidism. *Archives of Gastroenterology and Hepatology*, 2018, **1**(1): 22-25.
- [9] Bouomrani S, Regaieg N, Belgacem N, *et al.* Myositis-Like Syndrome Revealing Hypothyroidism. *Archives of Diabetes and Endocrine System*, 2018, **1**(2): 1-3.
- [10] Kate S, Dhanwal DK, Kumar S, *et al.* Acute psychosis as a presentation of hypopituitarism. *BMJ Case Rep*, 2013. pii: bcr2012008516.
- [11] Hernandez-Ramrez DA, Castellanos-Jurez JC, Romero T, *et al.* Mixedematous ileus; acute abdomen exacerbate. *Rev Gastroenterol Mex*, 2008, **73**(4): 231-234.
- [12] Lmanov Z. Thyroid disease in the elderly. *Vnitr Lek*, 2018, **64**(11): 993-1002.
- [13] Talaei A, Rafee N, Rafei F, *et al.* TSH cut off point based on depression in hypothyroid patients. *BMC Psychiatry*, 2017, **17**(1): 327.
<https://doi.org/10.1186/s12888-017-1478-9>
- [14] Bathla M, Singh M, Relan P. Prevalence of anxiety and depressive symptoms among patients with hypothyroidism. *Indian J Endocrinol Metab*, 2016, **20**(4): 468-474.
<https://doi.org/10.4103/2230-8210.183476>
- [15] Samuels MH. Psychiatric and cognitive manifestations of hypothyroidism. *Curr Opin Endocrinol Diabetes Obes*, 2014, **21**(5): 377-383.
<https://doi.org/10.1097/MED.0000000000000089>
- [16] Feldman AZ, Shrestha RT, Hennessey JV. Neuropsychiatric manifestations of thyroid disease. *Endocrinol Metab Clin North Am*, 2013, **42**(3): 453-476.
<https://doi.org/10.1016/j.ecl.2013.05.005>
- [17] Davis JD, Tremont G. Neuropsychiatric aspects of hypothyroidism and treatment reversibility. *Minerva Endocrinol*, 2007, **32**(1): 49-65.
- [18] Sathya A, Radhika R, Mahadevan S, *et al.* Mania as a presentation of primary hypothyroidism. *Singapore Med J*, 2009, **50**(2): e65-67.
- [19] Trachtenberg E, Passos IC, Kleina WW, *et al.* Hypothyroidism and severe neuropsychiatric symptoms: a rapid response to levothyroxine. *Braz J Psychiatry*, 2012, **34**(4): 501-504.
<https://doi.org/10.1016/j.rbp.2012.04.003>
- [20] Zavareh AT, Jomhourri R, Bejestani HS, *et al.* Depression and Hypothyroidism in a Population-Based Study of Iranian Women. *Rom J Intern Med*, 2016, **54**(4): 217-221.
<https://doi.org/10.1515/rjim-2016-0033>
- [21] Fugger G, Dold M, Bartova L, *et al.* Comorbid thyroid disease in patients with major depressive disorder - results from the European Group for the Study of Resistant Depression (GSRD). *Eur Neuropsychopharmacol*, 2018, **28**(6): 752-760
<https://doi.org/10.1016/j.euroneuro.2018.03.011>
- [22] Siegmann EM, Miller HHO, Luecke C, *et al.* Association of Depression and Anxiety Disorders With Autoimmune Thyroiditis: A Systematic Review and Meta-analysis. *JAMA Psychiatry*, 2018, **75**(6): 577-584.
<https://doi.org/10.1001/jamapsychiatry.2018.0190>
- [23] Tayde PS, Bhagwat NM, Sharma P, *et al.* Hypothyroidism and Depression: Are Cytokines the Link? *Indian J Endocrinol Metab*, 2017, **21**(6): 886-892.
https://doi.org/10.4103/ijem.IJEM_265_17
- [24] Ayala AR, Danese MD, Ladenson PW. When to treat mild hypothyroidism. *Endocrinol Metab Clin North Am*, 2000, **29**(2): 399-415.
[https://doi.org/10.1016/S0889-8529\(05\)70139-0](https://doi.org/10.1016/S0889-8529(05)70139-0)