

CASE REPORT

A case of life threatening acute Nivolumab induced autoimmune haemolytic anaemia

Abdul Rehman Farooq^{1*} Clodagh Keohane² Maeve Crowley³ Laura Whelan⁴ Neasa Gallwey⁴ Claire Brady⁴ Seamus O'Reilly^{1,5,6}

¹ Department of Medical Oncology, Mercy university hospital, Cork, Ireland

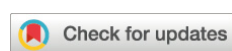² Department of Hematology, Mercy University Hospital, Cork, Ireland

³ Department of Haematology, Cork University Hospital, Cork, Ireland

⁴ UCC Cancer Trials Group at Cork University Hospital, Cork, Ireland

⁵ Cancer Research at UCC, University College Cork, Cork, Ireland

⁶ Cancer Trials Ireland, Dublin, Ireland



*Correspondence to: Abdul Rehman Farooq, Department of Medical Oncology, Mercy University Hospital, Cork, Ireland; Email: ar.farooq@gmail.com

Received: March 14, 2022;

Accepted: May 5, 2022;

Published: May 10, 2022.

Citation: Farooq AR, Keohane C, Crowley M, *et al.* A case of life threatening acute Nivolumab induced autoimmune haemolytic anaemia. *Curr Cancer Rep*, 2022, 4(1): 133-138.
<https://doi.org/10.25082/CCR.2022.01.002>

Copyright: © 2022 Abdul Rehman Farooq *et al.* This is an open access article distributed under the terms of the [Creative Commons Attribution License](https://creativecommons.org/licenses/by-nc/4.0/), which permits unrestricted use, distribution, and reproduction in any medium, provided the original author and source are credited.



Abstract: Autoimmune haemolytic anemia is a rare but potentially catastrophic adverse event of immune checkpoint inhibitor therapy. We present the case of a gentleman who presented with non-specific symptoms while undergoing adjuvant Nivolumab therapy after potentially curative surgery for gastroesophageal cancer. The patient's haemoglobin deteriorated to 4.7 g/dl with no evidence of bleeding and serologic tests indicative of hemolysis. He received emergent massive RCC transfusion receiving 9 units of bloods in 1 night, and was commenced on high dose methylprednisolone. During subsequent weeks of inpatient care, the patient continued to receive multiple daily red cell transfusions and had a total of 53 RCC transfusions during admission, along with high doses of steroids, 4 doses of weekly Rituximab as well as 2 doses of IVIG. While he was discharged on day 38 of admission, he required a slow taper of steroids over 6 months. Immune related hemolytic anemias are a rare corollary of immune check point inhibitors. The cases of immune related AIHA documented in the literature were treated with steroids, Rituximab and IVIG, which are also recommended by guidelines for the treatment of immune related haemolytic anemias.

Keywords: autoimmune haemolytic anemia, Nivolumab, hemolysis, hematologic toxicity, immunotherapy, immune related toxicity

1 Introduction

Immune checkpoint inhibitors (ICI) have revolutionised the treatment landscape in oncology during the past decade. These agents have been extensively developed for the treatment of patients with metastatic cancer and are now increasingly used in pre and post operative curative cancer settings. However patients treated with ICI are at risk of developing several immune related adverse events, with endocrine, dermatologic, gastrointestinal and pulmonary toxicities being commonly described [1–3]. Autoimmune hemolytic anemia remains a rare but potentially catastrophic adverse event of ICI therapy [4–6]. We present the case of a gentleman who presented with life threatening acute autoimmune hemolytic anemia after receiving adjuvant nivolumab therapy after potentially curative surgery for gastroesophageal cancer.

2 Case

The patient had initially presented with locally advanced, moderately differentiated adenocarcinoma of the distal oesophagus complicating Barrett's oesophagus.

He was treated with neoadjuvant chemoradiation using the CROSS (paclitaxel/ carboplatin) protocol [7]. The patient subsequently had a minimally invasive oesophagectomy. Pathology assessment demonstrated a residual ypT3 ypN1 tumor. The patient was then enrolled on the Checkmate 577 trial (NCT 02743494) which was a global, randomized, double-blind, placebo-controlled phase 3 trial assigning patients to receive adjuvant nivolumab or placebo for one year. This treatment was complicated by occasional episodes of hypoglycaemia despite carbohydrate loading due to postoperative gastrointestinal changes, and to balanitis. Treatment was otherwise

well tolerated up until completion of 1 year of study treatment. CT Thorax, abdomen and pelvis at the end of the treatment period showed no evidence of metastatic disease.

Approximately two weeks after his final cycle of the study drug, the patient presented acutely with a three day history of headaches, fatigue, pyrexia, muscle aches and decreased exercise tolerance. On admission, he was diaphoretic. Vital sign assessment demonstrated that he was afebrile and normotensive with a heart rate of 87, respiratory rate of 15 breaths per minute and normal oxygen saturation (Table 1). Initial admission blood tests demonstrated a haemoglobin of 13.6 g/dl, white cell count of $6.6 \times 10^9/L$, C-reactive protein of 66 mg/dl and total bilirubin 23.6 $\mu\text{mol/L}$. SARS-CoV-2- testing was negative. Radiographs of the chest and abdomen were normal. He was commenced on empiric co-amoxiclavulanic acid for pyrexia of unknown origin but remained febrile and was escalated to Piperacillin-Tazobactam therapy within 24 hours, along with addition of Valacyclovir.

Table 1 Vital signs of patient at admission

Vital sign	Value
Heart rate	87 bpm
Respiratory rate	15 bpm
Oxygen saturation	100%
Temperature	36.8°C
Blood Pressure	128/70 mmHG

In the ensuing days, fever persisted, and jaundice and fatigue developed Antibiotic therapy was broadened with gentamicin. Blood cultures were negative for infective organisms. On day 4 he suffered an episode of loss of consciousness. Repeat testing for SARS CoV 2 was negative. Urgent repeat testing demonstrated a Haemoglobin of 4.7 g/dl without clinical evidence of active bleeding, haematocrit 0.140 L/L, a reticulocyte count of $70 \times 10^9/L$, and an elevated lactate dehydrogenase level of 1504 U/L. He was subsequently admitted to the intensive care unit. Attempts to obtain compatible blood products were challenging due to extensive hemolysis (Figure 1) and he initially received 9 units of red cells overnight. Given his acute decline and high likelihood of autoimmune haemolytic anaemia (AIHA), methylprednisolone 1 gram was administered in the early hours of the morning of day 5 of admission. Serological testing showed direct antiglobulin testing was 4+IGG and 3+ C3d-. The trial team were urgently contacted and the patient was unblinded revealing that he had been receiving nivolumab therapy.

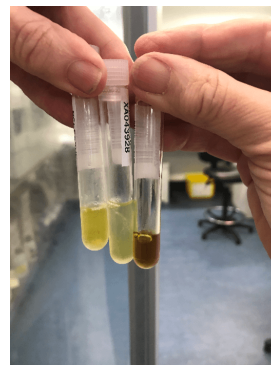


Figure 1 Patients Serum sample with severe haemolysis on the right hand side versus two normal serum samples

The American Society of Clinical Oncology (ASCO) 2018 guidelines on management of immune related adverse events were consulted [8] and he was commenced on methylprednisolone 2mg/kg/day. He continued to receive red cells aiming initially for a haemoglobin > 10 g/dl and subsequently 7 g/dl. Given the low reticulocyte count and slow bone marrow recovery despite folic acid and high dose steroids, a bone marrow biopsy was performed on day 6 of admission. Erythroid precursors represented 50% of total nucleated cell count. There was marked erythroid precursor without megakaryocyte change, consistent with active haemolysis.

Due to persistent fevers, antibiotic therapy was escalated to meropenem for one week on day 10 of admission. Daily lactate dehydrogenase, reticulocyte count and bilirubin were monitored. Methylprednisolone dose was initially decreased to 1mg/kg on day 8, but needed to be increased again to 2 mg/kg after a further 6 days. It was then reduced to 1 mg/kg day 18 of admission, then switched to oral prednisolone 1 mg/kg/day day 28 of admission and this began to be slowly tapered from day 36 of admission. This was supplemented by weekly rituximab for four doses commenced on day 7 of admission and intravenous immunoglobulin 1 mg/kg/day over two days,

on days 13 and 14 of admission. The patient’s antibiotics were stopped on day 17 of admission as patient was no longer thought to have an active infection.

The rate of hemolysis and resultant drop in haemoglobin was initially rapid (Figure 2). As the patient was felt to be peri-arrest, he was transfused a group specific rather than fully cross matched unit of RCC in order to commence the transfusion emergently. Red cell transfusion requirements were initially high with AI requiring on average 5 units of red cells daily and on one occasion received 9 units of red cells in a single day. This requirement slowly reduced over a five week period (Figure 3). He received 53 units of red cells in total during admission. Nasojeunal feeding was initiated between weeks 2 to 5 of admission to maintain appropriate calorie intake as well as for its association with improved physiologic and gut function and improved patient outcomes. Physiotherapy was initiated to reduce the impact of deconditioning and steroid associated proximal myopathy. The patient was discharged home on day 38 of admission. At the time of discharge his HB was 8.8 g/dl without needing recent transfusions and he was clinically well and vitally stable.

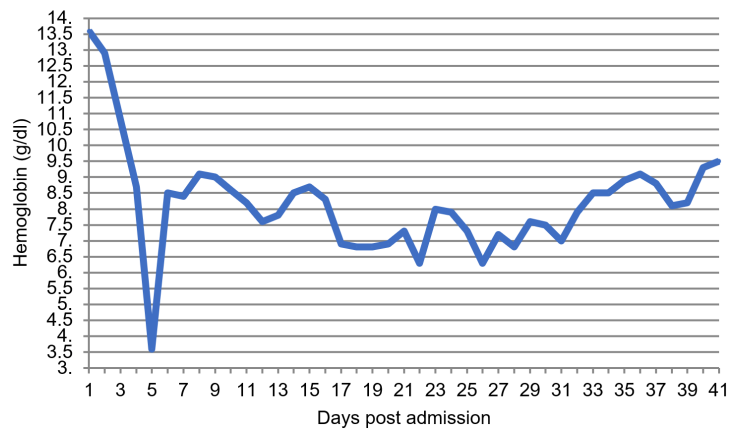


Figure 2 Patient’s hemoglobin level (g/dl) during hospital stay

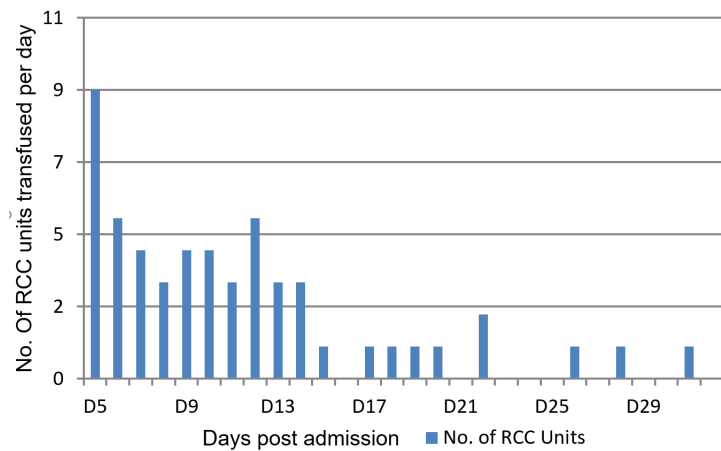


Figure 3 Daily RCC transfusions received by patient during hospital stay

The patient’s clinical course post discharge was marked by ongoing hemolysis which required a cautious and slow taper of steroids. Steroids continued on a slow taper of nearly 4 months after discharge during which his haemoglobin slowly improved to 13 g/dl, and his reticulocyte count returned to normal. The patient remained clinically well, and was continued on folic acid as well as prophylaxis for opportunistic infections with Co-Trimoxazole during this time. He subsequently remains well and in remission.

3 Patient perspective

In the month before admission to hospital I began to notice my legs had become increasingly tired. I was not worried about this as my work was physically demanding and I was on my feet for most of the day. I felt a sense of relief when I received my final treatment in that month. I felt well and had experienced few side effects apart from some minor skin irritations. Having no obvious side effects made me question if I was receiving the placebo or the trial drug nivolumab.

At the beginning of the month that I was admitted to hospital, I went golfing with my son. I began to sweat profusely and felt very weak while on the golf course. I returned to the car to rest and have a snack as I thought my blood sugar may be low. We came home and I rested and felt fine for a few days. The following Friday morning I woke up again sweating profusely: the bed sheets were saturated. My wife checked my temperature I had a low grade temp and took two panadol. She then contacted the GP and trials team and I was advised to attend the Accident and Emergency Department. I had a negative COVID test which this brought a huge sense of relief as that was my biggest concern at the time. I was admitted as I continued to sweat and have a temperature I also began to feel very lethargic. I was not overly worried as I thought I had some kind of infection and hoped to be home again in a few days.

As the weekend progressed I felt my condition continue to deteriorate. On the Sunday morning as I attempted to go to the bathroom I fainted and was incontinent of urine. The nursing staff assisted me back to bed as I could not stand up. I was very frightened upset and embarrassed. I rang my wife and told her there was something seriously wrong and I did not know what was happening to me. She then became very worried and felt helpless as she could not visit due to COVID restrictions.

I have no memory of what unfolded in the following days. I was later told that my family were called into the hospital in the early hours of Tuesday morning as my condition continued to deteriorate and I was in a critical condition. I have no recollection of any of these events and I do not remember my family by my bedside.

I have some vague recollection of waking up in intensive care an environment which felt very alien to me. I felt panicked as I did not know what had happened to me and why I ended up there. I found the intensive care environment very upsetting and stressful. I was later moved to the Coronary Care Unit which eased my tension somewhat. I do not know how long I was in Coronary Care as each day rolled into the next. My medical team kept me informed at all times and gave me ample opportunity to ask questions however I was too weak to comprehend the enormity of the situation.

Thankfully my wife was allowed to visit on a daily basis while I remained in a critical condition. I thought about my own mortality on more than one occasion my wife and I spoke about it openly which I found very comforting. I was never in denial about the seriousness of my situation but I never gave up hope.

There was a sense of relief when I was transferred to the ward however this relief was edged with nervousness due to the COVID surge in the community and the hospital. My family were no longer allowed to visit but I was delighted that I was well enough to communicate on the phone. I was elated the morning my consultant told me I was being discharged and I immediately called my wife to collect me.

I have very mixed emotions when I reflect on this experience. I am very thankful that I survived such an event but I also feel a certain amount of anger that I was one of the very few to develop such a rare side effect to this drug. I do not regret having participated in the trial as I am hopeful I will benefit from it in the long term.

4 Discussion

The incidence of AIHA is approximately 100-300 per million per year, with a prevalence of approximately 170 per million [9]. Drug induced immune haemolytic anemias are rare, occurring in 1 in 1 million of the population [10]. Medications including antibiotics such as cephalosporins and penicillins have been thought to cause AIHA, with a 2009 article reporting Cefotetan, Ceftriaxone and Piperacillin as the most common causes of drug induced immune haemolytic anemia [10, 11]. With the advent of ICIs, there have been multiple cases reported of AIHA secondary to their use [4]. The mechanism this is thought to take place is by random activation of the immune system resulting in formation of autoantibodies, activation of T cell clones, and diminished regulatory T cells [4].

Hemolytic anemias remain a rare corollary of the use of ICIs. One estimate of the frequency of AIHA secondary to ICIs put the figure at less than 0.1% or possibly 0.05% [4]. An analysis showed that only 0.211, 0.146, and 0.245 percent of patients suffered from AIHA secondary to treatment with nivolumab, pembrolizumab and atezolizumab respectively [4]. It also reported that out of 12 cases of AIHA secondary to ICI, 8 patients had been on nivolumab while an additional 2 had a combination of nivolumab and ipilimumab [4]. A French study assessed hematologic immune related adverse events secondary to ICI, noted that out of 35 patients, 9 patients (26%) had AIHA [5]. Severity of the adverse event was grade 3 in 1 patient and grade 4 in 8 patients [5]. The study also observed that all of these 9 patients had direct anti-globulin positive with 6 patients with positive C3d and 3 patients with positive IgG. Our patient similarly

had direct antiglobulin test positive with positivity for IgG and C3d. Our patient also underwent a bone marrow biopsy to further investigate his condition. Bone marrow biopsy has been recommended in the literature as part of the workup for an autoimmune haemolytic anemia in selected patients to rule out a lymphoproliferative disorder [11].

AIHA is a decompensating acquired hemolysis that develops as a result of the body's own immune system targeting antigens found on red blood cells with complement activation associated as well [12]. It is characterised as primary when no underlying disease is present. Secondary AIHA is commonly associated with a variety of conditions including lymphoproliferative disorder, autoimmune diseases, congenital syndromes and deficiencies as well as a number of medications as in this case [9]. The T-lymphocyte system plays an important part in the pathogenesis of AIHA, with the cytotoxic T-lymphocyte antigen 4 (CTLA-4) and programmed cell death 1 (PD-1) playing a role in immune tolerance [13]. Pharmacologic inhibition of PD-1 as with Nivolumab, therefore, leads to an increased risk of developing AIHA. In terms of management, the recently updated ASCO guideline on management of immune related adverse events recommends the use of high dose steroids as Prednisolone 1-2 mg/kg per day as first line therapy [14]. They also recommend that in case of no improvement, the use of immunosuppressive drugs, such as rituximab, IVIG, cyclosporine and infliximab should be considered [14]. In the present case the patient was treated aggressively with frequent blood transfusion, high dose of steroids along with four doses of weekly rituximab and 2 doses of IVIG. This corresponds to the management of other patients detailed in the literature. An analysis of patients reported in the literature with AIHA secondary to ICI showed that of 12 cases reported, 11 were treated with steroids, 3 received rituximab and 1 received IVIG [4]. The analysis showed that while most patients responded to treatment, the condition was fatal in 2 of 12 patients. Another analysis of AIHA cases from 3 French registries showed that out of 9 patients with AIHA, 4 required steroids only while 5 required additional treatment with rituximab [5].

The results of the Checkmate 577 trial have recently been published [15]. The median disease free survival was 22.4 months as compared to 11 months in favor of nivolumab. These results are practice changing and have led Nivolumab to become a standard of care in this population. Grade 3 or 4 adverse events of any cause occurred in approximately 34% of patients on nivolumab and approximately 32% of patients on placebo. About 13% of patients on nivolumab in the study experienced grade 3 or 4 treatment related adverse events. The most common grade 3 or 4 adverse events were fatigue, diarrhoea, rash, pruritus and raised aspartate transaminase (AST) [15]. Hematologic immune related adverse events were not described as part of the results, which illustrates how rare these adverse effects are.

In conclusion, we detail the case of a patient with severe AIHA secondary to ICI. The agent was given in the adjuvant setting as part of a clinical trial and the AIHA was life threatening, rapid in onset and occurred after treatment was completed. Such events may well become more frequent as ICI become established agents in the adjuvant setting in cancer care, and more patient receive therapy with them. While this patient's case was ultimately successfully managed it was challenging with respect to the rate of onset of symptoms, to the insidious nature of presentation, to the magnitude of the refractory fall in hemoglobin, and to the prolonged and significant degree of blood product support.

Conflict of interest

The authors declare that there is no conflict of interest.

Funding

The clinical trials unit is funded through the Health Research Board (Project No. CTIC-2021-002), UCC Cancer Trials Group, University College Cork, HRB Cancer Trials in Ireland, 2021.

References

- [1] Abdel-Rahman O, Eltobgy M, Oweira H, *et al.* Immune-related musculoskeletal toxicities among cancer patients treated with immune checkpoint inhibitors: a systematic review. *Immunotherapy*, 2017, **9**(14): 1175-1183. <https://doi.org/10.2217/imt-2017-0108>

- [2] Kuswanto WF, MacFarlane LA, Gedmintas L, *et al.* Rheumatologic symptoms in oncologic patients on PD-1 inhibitors. *Seminars in Arthritis and Rheumatism*, 2018, **47**(6): 907-910.
<https://doi.org/10.1016/j.semarthrit.2017.10.018>
- [3] Khoja L, Day D, Chen WW, *et al.* Tumour- and class-specific patterns of immune-related adverse events of immune checkpoint inhibitors: a systematic review - ScienceDirect. *Annals of Oncology*, 2017, **28**(10): 2377-2385.
<https://doi.org/10.1093/annonc/mdx286>
- [4] Tanios GE, Doley PB and Munker R. Autoimmune hemolytic anemia associated with the use of immune checkpoint inhibitors for cancer: 68 cases from the Food and Drug Administration database and review. *European Journal of Haematology*, 2019, **102**(2): 157-162.
<https://doi.org/10.1111/ejh.13187>
- [5] Delanoy N, Michot JM, Comont T, *et al.* Haematological immune-related adverse events induced by anti-PD-1 or anti-PD-L1 immunotherapy: a descriptive observational study. *Lancet Haematol*, 2019, **6**(1): e48-e57.
[https://doi.org/10.1016/S2352-3026\(18\)30175-3](https://doi.org/10.1016/S2352-3026(18)30175-3)
- [6] Davis EJ, Salem J, Young A, *et al.* Hematologic Complications of Immune Checkpoint Inhibitors. *The Oncologist*, 2019, **24**(5): 584-588.
<https://doi.org/10.1634/theoncologist.2018-0574>
- [7] Shapiro J, Van Lanschot JJB, Hulshof MCCM, *et al.* Neoadjuvant chemoradiotherapy plus surgery versus surgery alone for oesophageal or junctional cancer (CROSS): long-term results of a randomised controlled trial. *Lancet Oncology*, 2015, **16**(9): 1090-1098.
[https://doi.org/10.1016/S1470-2045\(15\)00040-6](https://doi.org/10.1016/S1470-2045(15)00040-6)
- [8] 2018 ASCO Guidelines on management of immune related adverse events. Accessed 05/11/2021.
<https://www.asco.org/sites/new-www.asco.org/files/content-files/practice-and-guidelines/2018-management-of-irAEs-summary.pdf>
- [9] Barcellini W, Fattizzo B, Zaninoni A, *et al.* Clinical heterogeneity and predictors of outcome in primary autoimmune hemolytic anemia: a GIMEMA study of 308 patients. *Blood*, 2014, **124**(19): 2930-2936.
<https://doi.org/10.1182/blood-2014-06-583021>
- [10] Garratty G. Drug-induced immune hemolytic anemia. *Hematology Am Soc Hematol Educ Program*, 2009, **2009**(1): 73-79.
<https://doi.org/10.1182/asheducation-2009.1.73>
- [11] Brodsky RA. Warm Autoimmune Hemolytic Anemia. *New England Journal of Medicine*, 2019, **381**(7): 647-654.
<https://doi.org/10.1056/NEJMcp1900554>
- [12] Hill A and Hill QA. Autoimmune hemolytic anemia. *Hematology Am Soc Hematol Educ Program*, 2018, **2018**(1): 382-389.
<https://doi.org/10.1182/asheducation-2018.1.382>
- [13] Berentsen S and Barcellini W. Autoimmune Hemolytic Anemias. *New England Journal of Medicine*, 2021, **385**(15): 1407-1419.
<https://doi.org/10.1056/NEJMra2033982>
- [14] Schneider BJ, Naidoo J, Santomasso BD, *et al.* Management of Immune-Related Adverse Events in Patients Treated With Immune Checkpoint Inhibitor Therapy: ASCO Guideline Update. *Journal of Clinical Oncology*, 2021, **39**(36): 4073-4126.
<https://doi.org/10.1200/JCO.21.01440>
- [15] Kelly RJ, Ajani JA, Kuzdzal J, *et al.* Adjuvant Nivolumab in Resected Esophageal or Gastroesophageal Junction Cancer. *New England Journal of Medicine*, 2021, **384**(13): 1191-1203.
<https://doi.org/10.1056/NEJMoa2032125>

(Edited by Snowy Wang)