

RESEARCH ARTICLE

Deciding whether to treat isolated mild dysplasia in infantile DDH: Identifying factors in decision making

Craig R Louer¹ James D Bomar² Jessica L Hughes³ Scott J Mubarak² Dennis R Wenger²
Vidyadhar V Upasani^{2*}

Abstract: Purpose There is significant variability in brace treatment indications for infantile acetabular dysplasia in the absence of hip dislocation or subluxation. This study's purpose was to evaluate characteristics of treated and untreated patients in our practice. **Methods** A retrospective chart review was performed of patients aged 0-12 months who were referred to orthopedics with concern for DDH. Demographic and clinical information, as well as provider and radiographic information were recorded for analysis. Five surgeons were independently asked to review de-identified radiographs and note which subjects warranted treatment. A consensus diagnosis of "dysplasia", "no dysplasia", or a lack of consensus were considered as independent variables. Univariate and Classification and Regression Tree (CART) analysis was performed to determine predictors of treatment. **Results** Mean acetabular inclination (30.6° vs. 28.2°; $p = 0.006$) and the incidence of abnormal abduction ($p = 0.002$) were higher for the group that was treated for dysplasia. CART analysis showed that patients with a consensus diagnosis of radiographic dysplasia were more likely to receive treatment than those without consensus, or a consensus of no dysplasia ($p < 0.001$). If consensus was not reached, then abnormal abduction on exam was the next strongest predictor of treatment ($p < 0.001$). Radiographic impression, which was the primary determinant of treatment, exhibited only fair intrarater and interrater reliability. **Conclusions** We studied factors that led to the diagnosis and treatment of DDH in an infant population. We observed that radiographic impression and abnormal abduction on exam were the only reliable factors predictive of treatment among our practice.

Keywords: mild acetabular dysplasia, DDH, DDH treatment decisions

1 Introduction

Infants are commonly referred to orthopedic surgeons for hip evaluation to rule out developmental dysplasia of the hip (DDH) following screening by a pediatrician. While the rate of a hip dislocation in the US is relatively rare (about 1 in 1000)^[1], the rate of acetabular dysplasia (under-coverage of the femoral head due to a poorly-developed acetabulum) is thought to be much higher. Because unrecognized or undertreated hip dysplasia is now known to be a contributor to degenerative hip disease as an adult^[2,3], treatment as a child is often recommended^[4].

While treatment methods such as hip orthoses or surgery can reliably improve acetabular dysplasia in the absence of dislocation or subluxation, there is no clear consensus on which patients require such treatment^[4-6]. Some of this uncertainty is rooted in the significant variability in measurement of the developing acetabulum and the inability to visualize the cartilage anlage with standard pelvis radiographs^[7]. More central to the debate is the lack of high-quality, long-term, comparative studies that help identify patients who would benefit from intervention^[8].

The purpose of this study was to investigate the relative importance of multiple clinical factors that lead to treatment of infantile acetabular dysplasia in the absence of hip dislocation or subluxation. History, exam, and radiographic data were considered in the treatment decision as well as the analysis. A retrospective, blinded review of radiographic images was also performed to determine the reliability of radiographic assessment in this clinical scenario. In the absence of high-level evidence about the treatment and long-term outcomes of this population, we feel that an expert consensus offers value by way of com-

Received: March 18, 2019 Accepted: April 8, 2020 Published: April 10, 2020

* Correspondence to: Vidyadhar V Upasani, Division of Orthopedics, Rady Children's Hospital, San Diego, 92123, USA; Email: vupasani@rchsd.org

¹ Division of Orthopedics, University of North Carolina, Chapel Hill, 27599, USA

² Division of Orthopedics, Rady Children's Hospital, San Diego, 92123, USA

³ Division of Orthopedics, Baylor Scott and White Temple, 76508, USA

Citation: Louer CR, Bomar JD, Hughes JL, et al. Deciding whether to treat isolated mild dysplasia in infantile DDH: Identifying factors in decision making. *Theory Clin Pract Pediatr*, 2020, 2(1): 32-37.

Copyright: © 2020 Vidyadhar V Upasani, et al. This is an open access article distributed under the terms of the [Creative Commons Attribution License](https://creativecommons.org/licenses/by/4.0/), which permits unrestricted use, distribution, and reproduction in any medium, provided the original author and source are credited.

parison for surgeons who also face this clinical dilemma.

2 Materials and methods

The Institutional Review Board (IRB) approved this study. Retrospective chart review was performed of patients aged 0-12 months who were referred to an orthopedic surgeon within our practice with concern for DDH due to a clinical finding of asymmetric thigh folds between 05/2014 and 02/2017. This population was chosen due to the clinical equipoise that exists within our center regarding the diagnosis of dysplasia in such patients. We feel that any selection bias brought on by this choice is minimal due to the weak link between skin folds and acetabular dysplasia (in the absence of dislocation/subluxation)^[9]. Patients were excluded if they were found to have a hip dislocation or subluxation, or incomplete clinical data.

Patient records were reviewed for demographics, historical factors such as birth order, family history of DDH, breech intrauterine positioning, and history of swaddling as a newborn. Exam findings such as asymmetric hip abduction or hip abduction <60° were recorded, in addition to any finding of other newborn disorders such as torticollis or clubfoot. Patient radiographs were then independently evaluated by a single grader who measured acetabular inclination for both AP and frog-lateral views. The radiographs analyzed were the first plain radiographs taken in the evaluation. Finally, the patient’s prescribed treatment and surgeon-specific factors were both noted.

To further investigate the nuances of radiographic diagnosis of dysplasia, we had each surgeon review initial radiographs from all patients in the cohort in a blinded fashion (including only patient age without other historical or exam data) to render a diagnosis and treatment plan. Results were compiled to determine which radiographs resulted in a consensus to treat versus not to treat, as well as those without consensus.

Basic descriptive statistics are presented. The child was used for the unit of analysis. In evaluating acetabular inclination, only the hip with highest acetabular inclination was included. The Shapiro-Wilk test of normality and Levene’s test of homogeneity of variances was performed

on all continuous data. All continuous data was found to be normally distributed and was analyzed with an analysis of variance (ANOVA). Pearson’s chi-square and Fisher’s exact test were used to evaluate categorical data. Fleiss kappa was used to evaluate inter- and intra-observer reliability when evaluating consistency in the radiographic diagnosis of DDH. The ratings of five surgeons were used for inter-rater reliability. Intra-rater reliability was evaluated by having three surgeons repeat their ratings a minimum of three weeks later. The classification and regression tree (CART) function within SPSS was utilized to construct a tree. Treatment was entered as the dependent variable, while age, sex, provider, provider experience, swaddling history, breech presentation, family history, first-born status, presence of torticollis, abnormal abduction, five surgeon consensus of dysplasia based on x-ray, initial presentation to clinic with an outside x-ray and x-ray reading, and acetabular inclination were entered as independent variables. Statistical significance was defined as p <0.05. Statistical analysis was performed using SPSS (version 25; IBM, New York, USA). No a priori power analysis was performed.

3 Ethics statement

This study was reviewed and approved by our Institutional Review Board and informed consent was not required for this study. All procedures performed in this study were in accordance with the ethical standards of the institutional research committee and with the 1964 Helsinki declaration and its later amendments or comparable ethical standards.

4 Results

There were 71 patients included in the study group. Average age was 6.3±2.1 months (range 2.5-10.8 months). Twenty-eight patients (39%) were diagnosed with dysplasia and treated with either a Pavlik harness (PH) or abduction brace (AB). The remaining 43 (61%) were determined to be normal and were not treated.

Twenty-seven patients were referred after having ra-

Table 1. Clinical history factors

	n	Age at Initial Visit (Months)		Sex		Swaddling History		Breech at Birth		Family History of DDH		Birth Order	
		Mean±SD	Range	Male	Female	Yes	No	Yes	No	Yes	No	First	Not First
Treatment	28	6.6±1.8	2.7 to 10.4	4	24	8	20	0	28	2	26	9	19
No Treatment	43	6.2±2.3	2.5 to 10.8	8	35	6	37	4	39	2	41	7	36
Total	71	6.3±2.1	2.5 to 10.8	12	59	14	57	4	67	4	67	16	55
p-value		0.416		0.753		0.130		0.148		0.640		0.118	

Table 2. Exam and imaging factors

	n	Acetabular Index at Initial Visit Mean±SD	Provider Experience		Five Physician DDH Dx on X-ray Alone			Abduction		Torticollis		Radiology Dx of DDH Prior to Ortho Visit (n=27)	
			Junior MD	Senior MD	All Agree DDH	All Agree No DDH	No Agreement	Normal	Abnormal	Torticollis	No Torticollis	Junior MD	Senior MD
Treatment	28	30.6±2.9°	14	14	11	2	15	15	13	2	26	7	7
No Treatment	43	*28.2±3.8°	16	27	2	11	30	38	5	2	41	4	9
Total	71	29.2±3.6°	30	41	13	13	45	53	18	4	67	11	16
p-value		0.006	0.286		0.001			0.009		0.644		0.44	

Note: * Four subjects in the No Treatment group had an ultrasound at initial visit and were excluded from AI analysis

diographs already taken. All of these presented with an associated radiology reading of a hip abnormality that indicated some degree of acetabular dysplasia. Given the multiple centers obtaining and interpreting radiographs, the threshold for diagnosing dysplasia by these radiologists was unclear. However, the presence of pre-existing radiograph (read as abnormal by a radiologist) was subsequently included as a clinical factor.

None of the demographic or clinical history factors influenced the decision to treat for dysplasia on univariate analysis (Table 1), including age, sex, swaddling history, breech, family history of DDH, or first-born status. With regards to exam or imaging factors, there were a few associations. Decreased or asymmetric abduction was more likely to be present in those that were treated versus those that were not treated (p = 0.002; Table 2). Mean acetabular inclination was higher for the treated group as well (30.6° vs. 28.2°; p = 0.006).

Consensus radiographic diagnosis was obtained on only 26 of 71 (37%) images, with 13 of those having a consensus diagnosis of dysplasia requiring treatment, and the other 13 thought to have no dysplasia and would not require treatment (Figure 1,2,3). Those patients with a retrospective consensus diagnosis of dysplasia were more likely to have been treated initially compared to those either without consensus, or a consensus of no dysplasia (p <0.001).

Provider level of experience, classified by junior or senior providers with a cutoff of 15 years experience (p = 0.331) and prior radiology reading of hip abnormality

(p = 0.094) did not affect treatment rates in the Univariate analysis. There was still no influence of prior radiologic reading when the group was sub-divided based on provider experience (p = 0.695).

CART analysis demonstrated that the most significant predictor of treatment for dysplasia was radiographic impression of DDH by the surgeon (p = 0.001; Figure 4). If all 5 providers agreed that the blinded radiograph was indicative of hip dysplasia, there was an 84.6% chance that the patient was actually treated for dysplasia. The only other factor found to influence treatment decision was a clinical exam finding of limited or asymmetric abduction (p <0.001), with a treatment rate of 75% when abnormal abduction was present even if radiographic evaluation did not result in a consensus diagnosis of DDH.

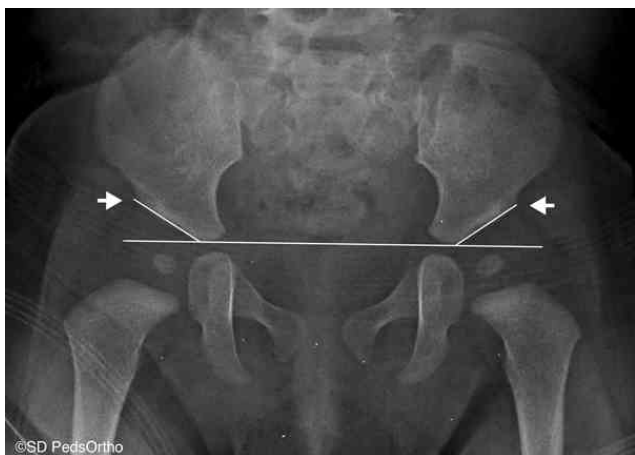Radiographic diagnosis of DDH often did not reach consensus (63% of patients had variable diagnosis and treatment plan depending on the surgeon). Inter-rater reliability was “fair” when considering measurements from the 5 different readers (k = 0.357, p <0.001). Intra-rater reliability for three readers was similar from time one to time two with k = 0.351, p <0.001. Additional details regarding inter- and intra-rater reliability can be found in Table 3.

5 Discussion and conclusion

Pediatric orthopedic surgeons are commonly faced with the decision as to how to best manage an infant with concern for acetabular dysplasia in the absence of dislocation

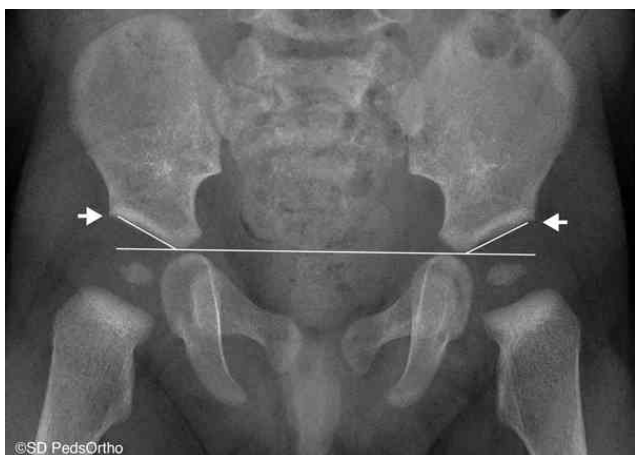Table 3. Inter- and intra-rater reliability of radiographic diagnosis of DDH based on initial x-rays alone

		Kappa	95% Confidence Interval		p-value
			Lower bound	Upper bound	
Inter-rater reliability	Five surgeons	0.357	0.285	0.429	<0.001
	Three surgeons combined	0.351	0.163	0.54	<0.001
Intra-rater reliability	Surgeon 1 (senior)	0.72	0.394	1.047	<0.001
	Surgeon 4 (senior)	0.497	0.17	0.823	0.003
	Surgeon 5 (junior)	-0.175	-0.501	0.152	0.294



Note: All five surgeons blinded to whether or not this patient received treatment agreed that this patient had DDH that should be treated based on this x-ray. This patient was ultimately treated with a Pavlik harness full time for three months, then transitioned to a hip abduction brace to be worn full time for an additional month. The brace was then recommended for nights and naps for an additional six months.

Figure 1. AP pelvis x-ray of a 5.4-month-old female



Note: Two surgeons felt that this patient had DDH that should be treated and the other three surgeons felt that this patient did not have DDH and required no treatment. This patient was treated with a Pavlik harness for 12-18 hours per day for four months.

Figure 2. AP pelvis x-ray of a 6.7-month-old male



Note: All five surgeons felt that this patient did not have DDH and did not require treatment. This patient was not treated.

Figure 3. AP pelvis x-ray of a 6.9-month-old female

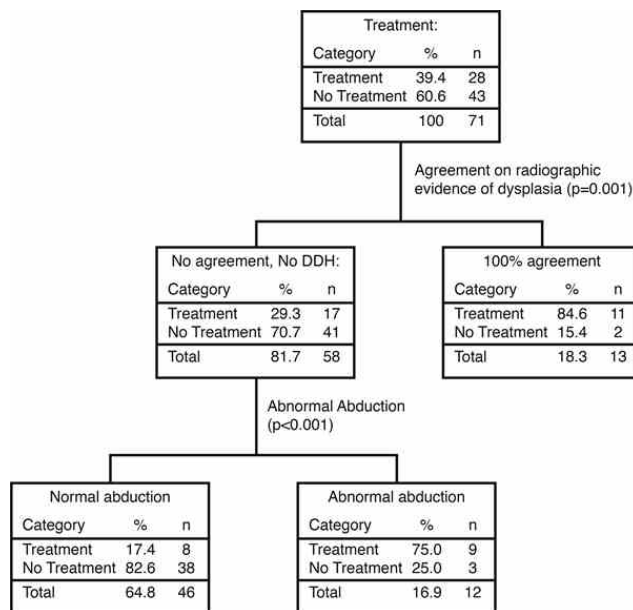


Figure 4. Classification and regression tree (CART) showing predictors of treatment

or subluxation. While accurate prediction of eventual hip longevity and function is limited with our current knowledge base, we can seek to better understand the factors that affect our treatment decisions.

We set out to identify factors that influenced the decision to treat infants for hip dysplasia within our practice environment. We determined that a radiograph diagnosed as DDH by 5 out of 5 surgeons is highly associated with a decision to treat for dysplasia. In addition, abnormal abduction on physical exam (defined as less than 60° or asymmetric) was an independent predictor of DDH treatment. Among all the criteria investigated, these are the only two that had a significant impact and led to a decision to brace.

Radiographic evaluation (with plain radiograph or ultrasound) has long been a critical factor in the treatment decisions for newborns with DDH and proved to be the most important factor in this study. However, the diagnosis of DDH using radiographic imaging is nuanced in the absence of a dislocation or subluxation, and criteria for what is abnormal is not always agreed upon. Additionally, the measurements used to determine normal vs abnormal are not always reliable from one reading to the next, including acetabular inclination^[7]. Even so, we did see a significant increase in the average acetabular inclination (AI) for the treated group versus the untreated group, although the difference of 2.4° is small, arguably clinically insignificant, and within error of measurement^[7,10].

Our study supports these prior conclusions about the difficulty of radiographic diagnosis. We note only fair

to poor reliability in the grading of these radiographs as dysplastic or not, with only 37% of them rendering a consensus diagnosis among all the surgeons. Our approach is unique in that we do not specify a single measurement for determining dysplasia, and instead ask for an overall diagnosis & treatment plan based off all available imaging features. Our graders use acetabular index to be a component of their grade, but they also make use of more nuanced factors such as blunting of the lateral edge of the acetabular sourcil, leg and pelvis position, asymmetry in proximal femoral epiphysis ossification, etc. Although these other factors cannot be represented by a continuous variable, rendering them more difficult to quantify and compare than acetabular inclination, we feel they still have diagnostic importance. Both consensus radiographic impression and acetabular inclination were associated with our treatment decision in the Univariate analysis. However, when the data was analyzed by multivariate regression (CART) analysis, the consensus radiographic impression remained vital and was an overall better predictor. Strict AI measurements likely still have a role to play in diagnosis of infantile DDH due their quantifiable nature, but there are other components that make up a surgeon's overall radiographic impression^[11].

When radiographs were equivocal or appeared to have no dysplasia, the physical exam findings of asymmetric abduction or abduction $<60^\circ$ also influenced the decision to initiate treatment for potential DDH. While Ortolani and Barlow tests are thought to be the mainstay of exam maneuvers in DDH, they are negative for located, stable hips that nonetheless have acetabular dysplasia. As expected, none of our patients had positive Ortolani or Barlow tests. Limited abduction has long been thought to represent a neglected dislocation^[12], but it has also been associated with hip dysplasia in many studies^[13-15].

While we did identify factors that influence the decision to treat for DDH in our center, the main limitation of this study is that we cannot determine whether these are the factors we *should* be using. Until we know the natural history of this population, we cannot give a value judgment on the accuracy of the diagnostic criteria. The other main limitation is the size of the cohort. We used a group of patients who were referred for asymmetric thigh folds to have a population that would not be skewed towards the presence of traditional clinical risk factors. We believe this represents a population of subtle dysplasia for which referring pediatricians and treating surgeons often find themselves with difficulty in diagnosis. As a result of this criteria, however, patient numbers are reduced, and the study is subject to type-II error, where we fail to make an association that is present. Conversely, we can be more confident about the importance of the factors that were

found.

In conclusion, we studied potential factors that led to the diagnosis and treatment of DDH in an infant population. Overall radiographic impression, if consensus about DDH was reached, was the strongest predictor of treatment for DDH. If consensus was not reached, then abnormal abduction on exam was the next strongest predictor for DDH treatment. No other factors proved to be significant in the determination of DDH. Given that there was still a nearly one in five (17.4%) chance of treating for dysplasia in the absence of these two factors, there clearly are other secondary factors involved. Even though the radiographic appearance was the most significant predictor of DDH treatment, we found that radiographic reliability was overall fair to poor and there is extreme variability among different surgeons, and within the same surgeon at different time periods, as to what they believe represents radiographic dysplasia. Future studies can consider incorporating surgeons from other pediatric centers for a more broadly applicable consensus. Registries that follow these children into adolescence and adulthood are essential to determining the necessity of treatment and to select those who are most likely to benefit.

Conflict of interest and funding

No external funding was received for this study. Authors 1-3 have nothing to disclose. Authors 4 and 5 have stock or stock option in Rhino Pediatric Orthopedic Designs, Inc. Author 6 is a paid presenter for BroadWater, DePuy, A Johnson and Johnson company, Nuvasive, and OrthoPediatrics. Author 6 receives research support from EOS Imaging and Pacira. Author 6 is a paid consultant for Globus Medical and OrthoPediatrics. Author 6 has stock or stock options in Imagen.

Acknowledgements

We would like to thank Maya Pring, MD and Doug Wallace, MD for their help with the radiographic review.

References

- [1] Godward S and Dezateux C. Surgery for congenital dislocation of the hip in the UK as a measure of outcome of screening. MRC Working Party on Congenital Dislocation of the Hip. Medical Research Council. Lancet, 1998, **351**(9110): 1149-1152.
[https://doi.org/10.1016/S0140-6736\(97\)10466-4](https://doi.org/10.1016/S0140-6736(97)10466-4)
- [2] Murphy SB, Ganz R and Müller ME. The prognosis in untreated dysplasia of the hip. A study of radiographic factors that predict the outcome. The Journal of Bone and Joint surgery. American volume, 1995, **77**(7): 985-989.
<https://doi.org/10.2106/00004623-199507000-00002>

- [3] Terjesen T. Residual hip dysplasia as a risk factor for osteoarthritis in 45 years follow-up of late-detected hip dislocation. *Journal of Children's Orthopaedics*, 2011, **5**(6): 425-431.
<https://doi.org/10.1007/s11832-011-0370-2>
- [4] Wenger DR . Is There a Role for Acetabular Dysplasia Correction in an Asymptomatic Patient? *Journal of Pediatric Orthopaedics*, 2013, **33**(supl 1): 8-12.
<https://doi.org/10.1097/BPO.0b013e3182771764>
- [5] Sarkissian EJ, Sankar WN, Baldwin K, et al. Is there a predilection for breech infants to demonstrate spontaneous stabilization of DDH instability? *Journal of Pediatric Orthopaedics*, 2014, **34**(5): 509-513.
<https://doi.org/10.1097/BPO.0000000000000134>
- [6] Gans I, Flynn JM and Sankar WN. Abduction bracing for residual acetabular dysplasia in infantile DDH. *Journal of Pediatric Orthopaedics*, 2013, **33**(7): 714-718.
<https://doi.org/10.1097/BPO.0b013e31829d5704>
- [7] Broughton N, Brougham D, Cole W, et al. Reliability of radiological measurements in the assessment of the child's hip. *Journal of Bone and Joint Surgery. British Volume*, 1989, **71**(1): 6-8.
<https://doi.org/10.1302/0301-620x.71b1.2915007>
- [8] Weinstein SL. The Importance of Natural History. *Journal of Pediatric Orthopaedics*, 2019, **39**(6): 6-9.
<https://doi.org/10.1097/BPO.0000000000001336>
- [9] Louer CR, Bomar JD, Pring ME, et al. Should paediatricians initiate orthopaedic hip dysplasia referrals for infants with isolated asymmetric skin folds? *Journal of Pediatric Orthopaedics*, 2019, **13**(6): 593-599.
<https://doi.org/10.1302/1863-2548.13.190090>
- [10] Boniforti FG, Fujii G, Angliss RD, et al. The reliability of measurements of pelvic radiographs in infants. *Journal of Bone and Joint Surgery. British Volume*, 1997, **79**(4): 570-575.
<https://doi.org/10.1302/0301-620x.79b4.7238>
- [11] Novais EN, Pan Z, Autruong PT, et al. Normal Percentile Reference Curves and Correlation of Acetabular Index and Acetabular Depth Ratio in Children. *Journal of Pediatric Orthopaedics*, 2018, **38**(3): 163-169.
<https://doi.org/10.1097/BPO.0000000000000791>
- [12] Paterson D. The early diagnosis and treatment of congenital dislocation of the hip[J]. *Australian & New Zealand Journal of Surgery*, 1976, **46**(4): 359-366.
<https://doi.org/10.1111/j.1445-2197.1976.tb03249.x>
- [13] Omeroğlu H and Koparal S. The role of clinical examination and risk factors in the diagnosis of developmental dysplasia of the hip: a prospective study in 188 referred young infants. *Archives of Orthopaedic & Trauma Surgery*, 2001, **121**(1-2): 7-11.
<https://doi.org/10.1007/s004020000186>
- [14] Stein-Zamir C, Volovik I, Rishpon S, et al. Developmental dysplasia of the hip: Risk markers, clinical screening and outcome. *Pediatrics International*, 2008, **50**(3): 341-345.
<https://doi.org/10.1111/j.1442-200X.2008.02575.x>
- [15] Stoffelen D, Urlus M, Molenaers G, et al. Ultrasound, Radiographs, and Clinical Symptoms in Developmental Dislocation of the Hip. *Journal of Pediatric Orthopaedics B*, 1995, **4**(2): 194-199.
<https://doi.org/10.1097/01202412-199504020-00012>